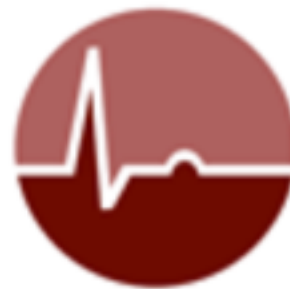

# Ultrasound-guided Shoulder Arthrocentesis

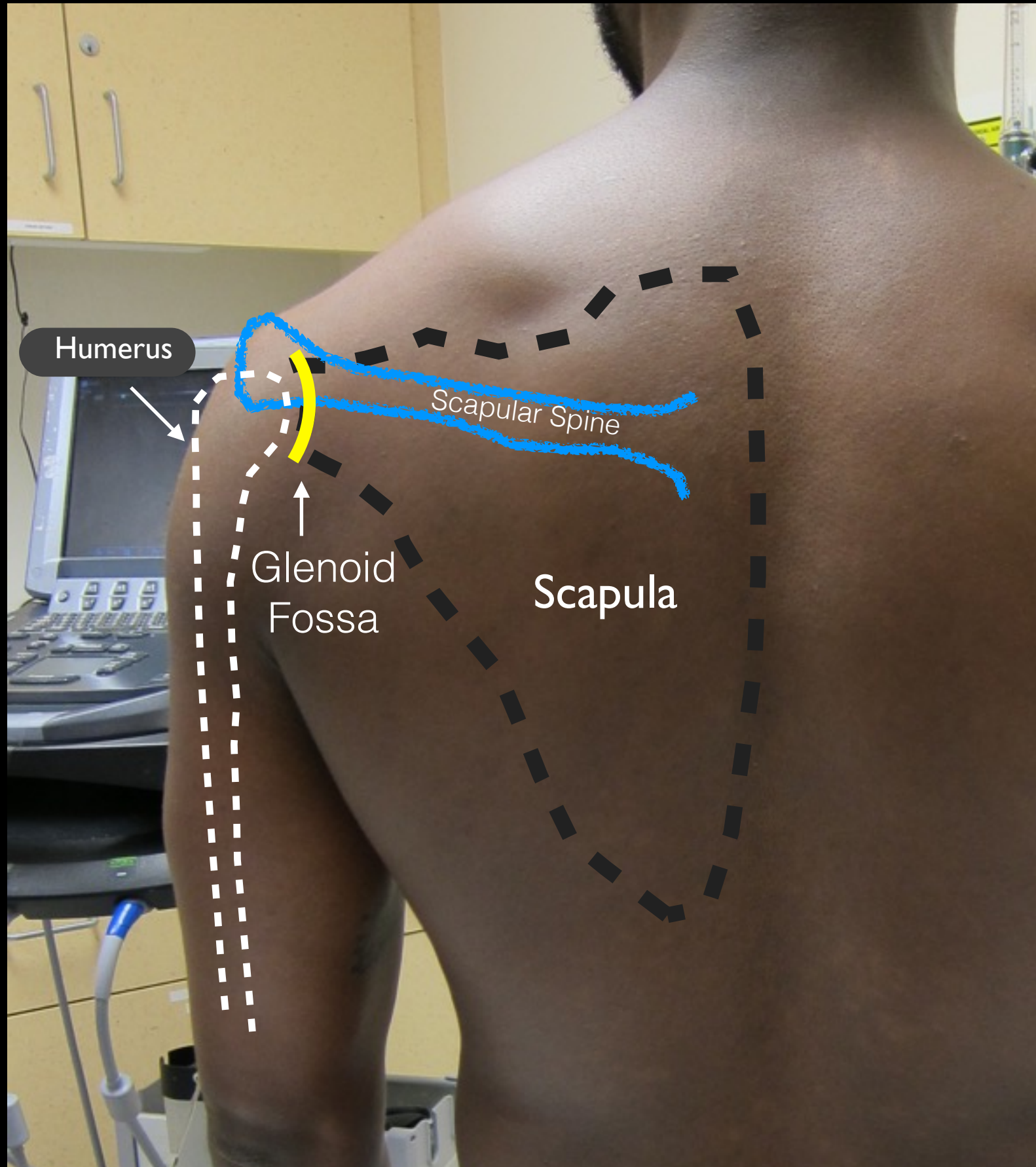
**HIGHLAND EMERGENCY**

DEPARTMENT OF EMERGENCY MEDICINE  
ALAMEDA HEALTH SYSTEM - HIGHLAND HOSPITAL



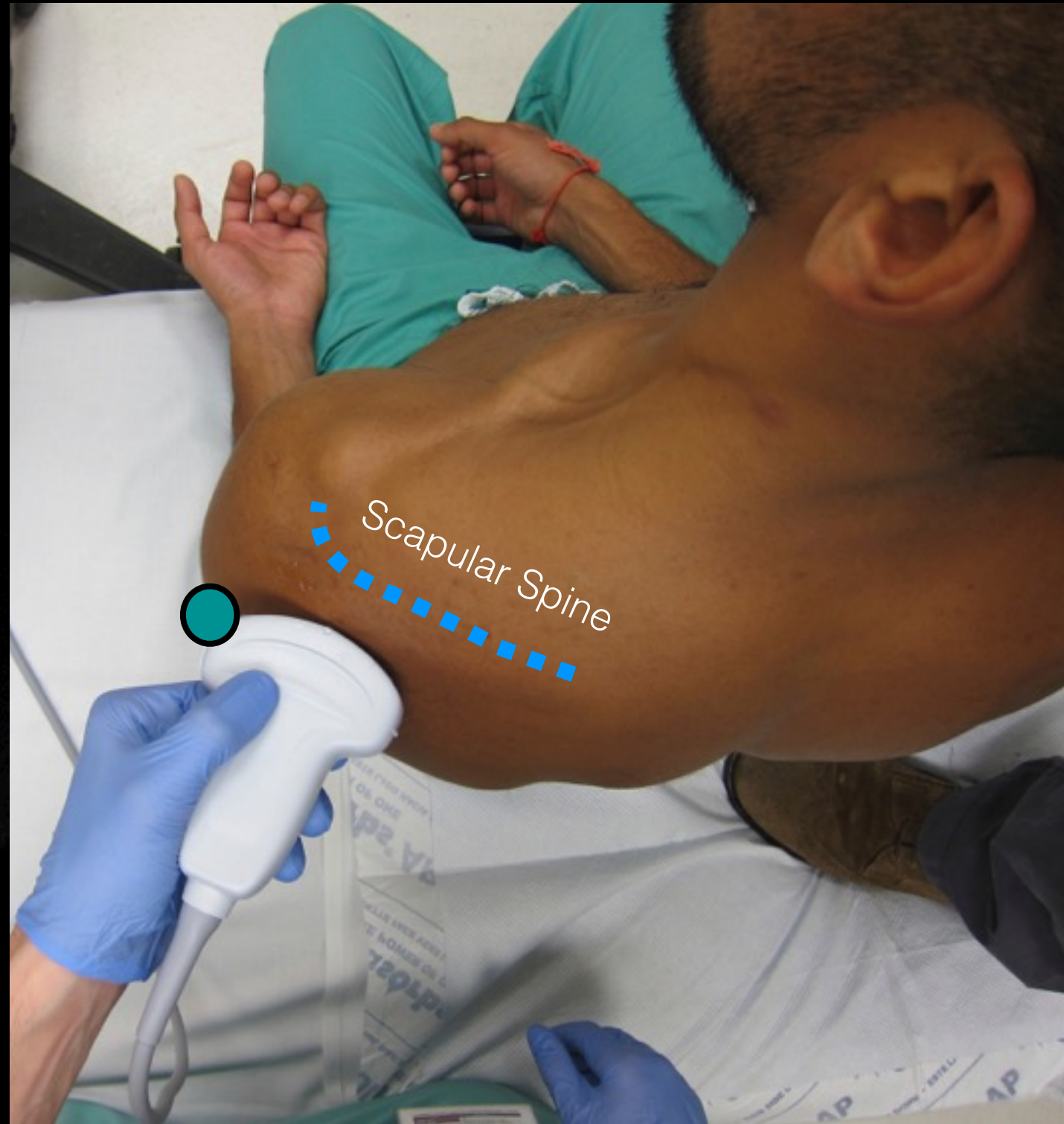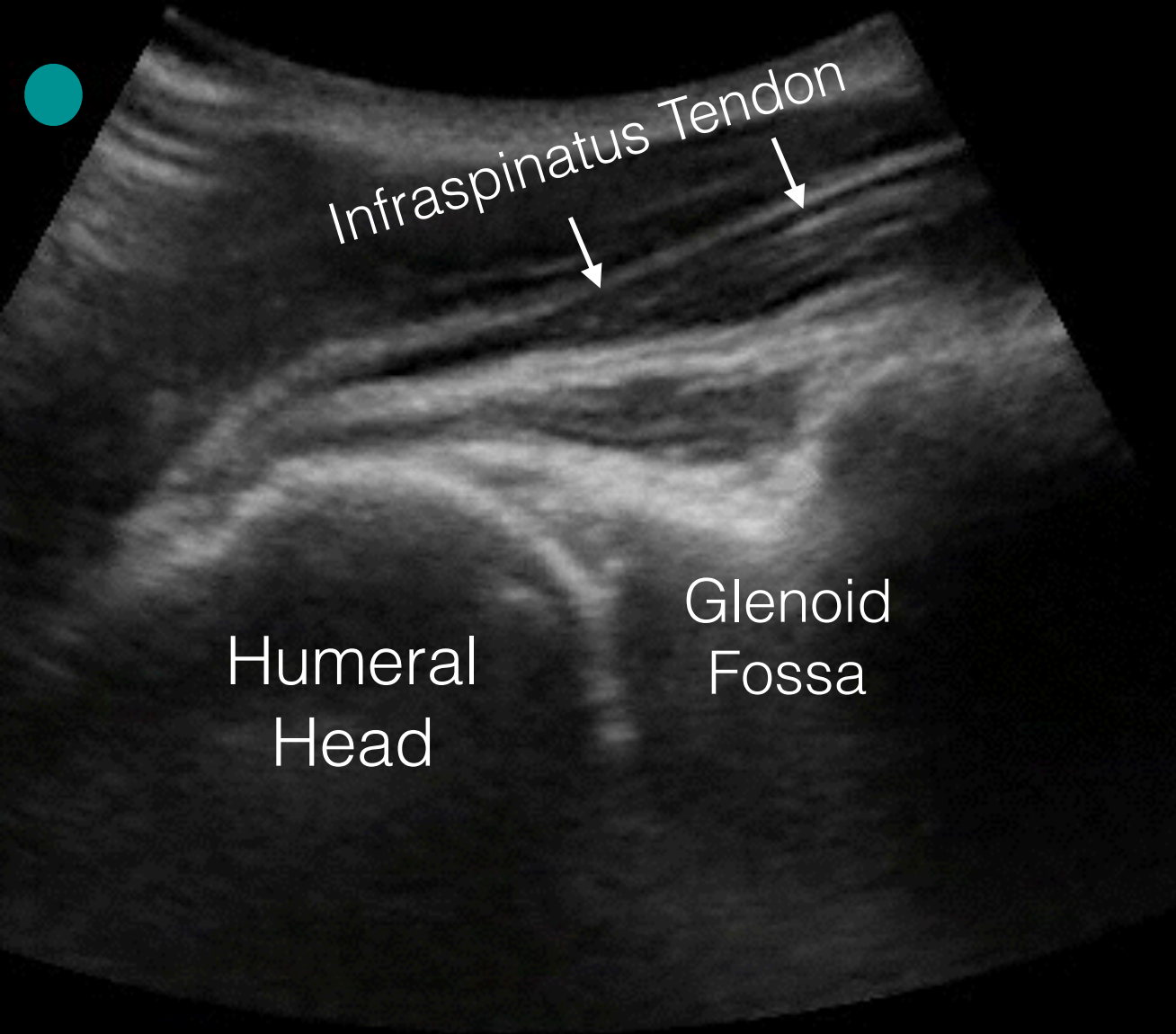
1

# Palpate the scapular spine



2

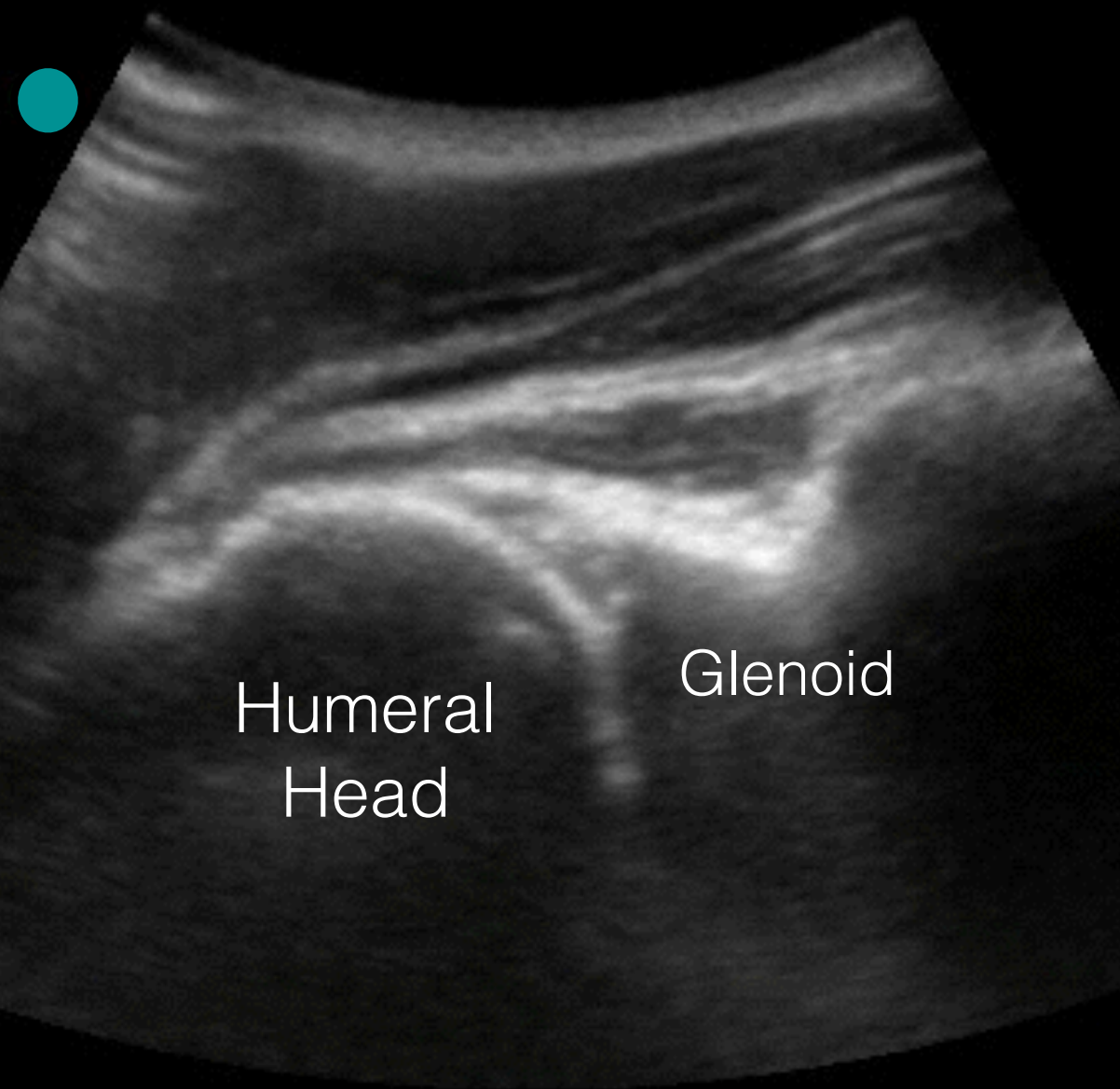
Transducer **parallel** to the bed



3

Clear View of **humeral head** and **glenoid fossa**

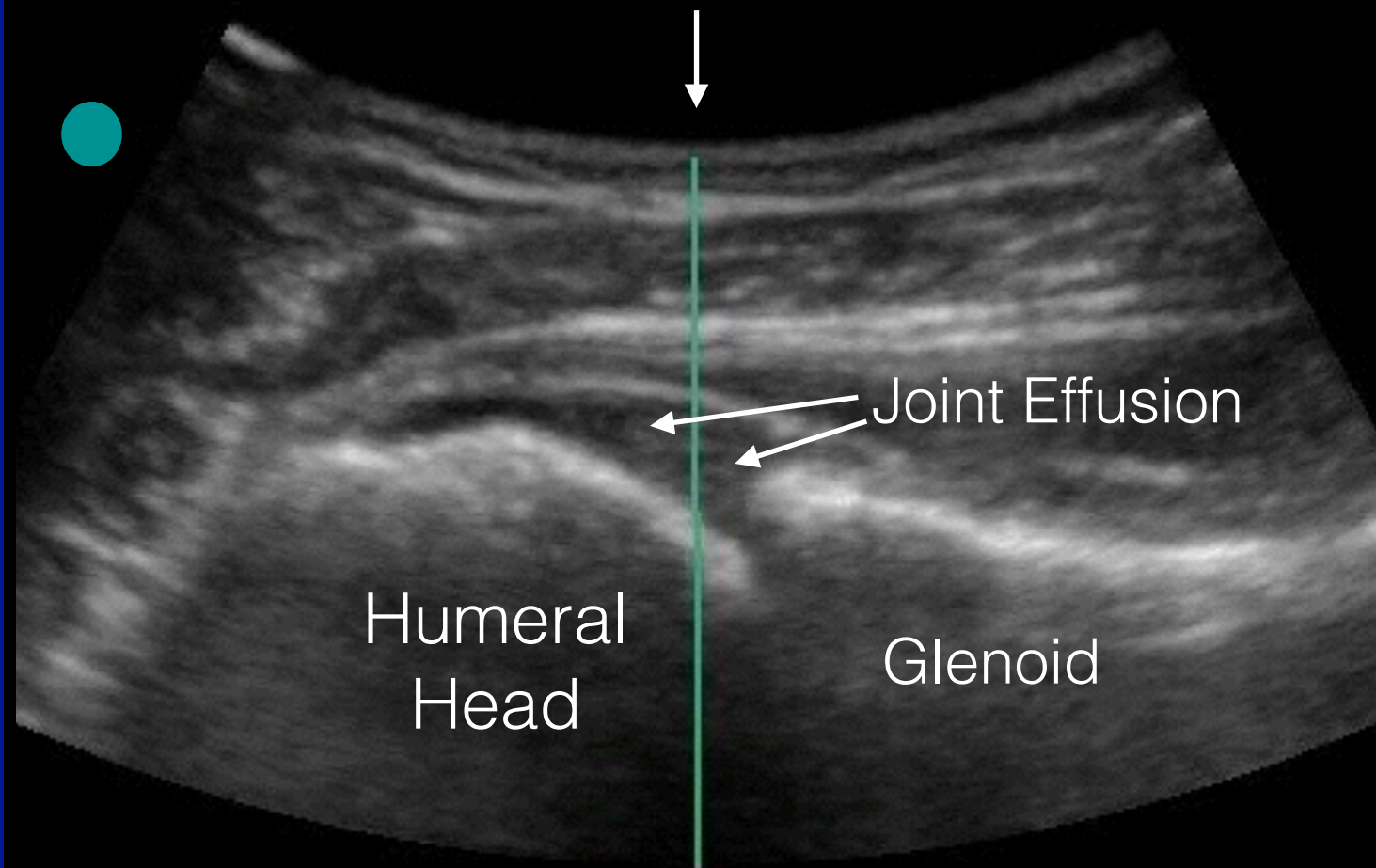




Humeral  
Head

Glenoid

Normal



M-mode marker



Joint Effusion

Humeral  
Head

Glenoid

Joint effusion

4

Aspirate just **below** the **scapular spine**

